

Leigh Syndrome in a Filipino Child: A Case Report



Michelle G. Sy, MD, Ma. Antonia Aurora Moral-Valencia, MD

ABSTRACT

Introduction: Leigh disease and Leigh-like syndrome are a heterogeneous group of neurodegenerative disorders involving any level of the neuraxis and may present with a variety of clinical presentations, prominent among them is psychomotor regression. Despite the remarkable number of established disease genes and novel mutations being discovered, many cases of Leigh syndrome remain without a genetic diagnosis, indicating that there are still more disease genes to be identified.

Case: Here we present a case of a two and a half-year-old girl who presented with delayed acquisition of developmental milestones with subsequent regression, ataxia, and dyskinesia. Her work-up showed raised blood lactate levels and lactate peak in MR spectroscopy. Mitochondria genome showed absence of mitochondrial DNA mutation, while whole exome sequence analysis revealed a novel dynein gene variant, p.A1577S. Her parents underwent genetic testing as well, and her father also had the same dynein mutation, however, is non-symptomatic. She had an older brother who initially presented with ophthalmoplegia and eventually developed psychomotor regression. He subsequently expired from respiratory failure after almost 2 years from initial presentation. Both siblings were diagnosed with Leigh syndrome.

Conclusion: The diagnosis of Leigh syndrome remains based on characteristic clinical and

radiologic findings. However, a specific defect must be identified if reliable genetic counseling is to be provided.

Key words: case report, neurodegenerative disease, mitochondrial disorder, Leigh syndrome, subacute necrotizing encephalopathy

INTRODUCTION

Leigh syndrome (aka subacute necrotizing encephalopathy) was first described by Denis Archibald Leigh in 1951 in a 7-month-old male infant with post-mortem findings similar to Wernick's encephalopathy.[1] Since then, it has evolved into a clinical entity with heterogeneous phenotypic characteristics presenting as intellectual or motor retardation, often with accompanying regression, ataxia, dystonia, spasticity, hyperreflexia, hypotonia, muscle atrophy, metabolic acidosis, various brainstem dysfunctions including nystagmus, ophthalmoplegia, and respiratory abnormalities and a clinical course with rapid deterioration of cognitive and motor functions.[2-4] Transmission is through mitochondrial, X-linked or autosomal recessive transmission,[5] however, the genetic cause of a number of Leigh syndrome cases remains unknown.[5] Newly identified nuclear genetic causes are increasing, largely because of next generation and whole exome sequencing.[6] Despite its considerable heterogeneity, the basic neuropathological features in affected children are almost identical with bilaterally symmetrical involvement of brainstem, diencephalon, basal ganglia, and cerebellum exhibiting necrotic lesions associated with demyelination, vascular proliferation,

✉ Michelle G. Sy, MD
michgsymd@outlook.com

Section of Child Neurology and Developmental Medicine, The Department of Pediatrics and The Department of Neuroscience and Behavioral Medicine, University of Santo Tomas Hospital, Manila, Philippines

and gliosis. We report a case of Leigh syndrome that shows no identifiable genetic mutation.

CASE

Our patient is a two-and-a-half-year-old girl from Metro Manila and is the second child of non-consanguineous second marriages of both parents.

She was born of an uncomplicated pregnancy and delivery. After an expanded newborn screening, she had plasma amino acid analysis, urine metabolic screening and urine organic acid profile done at 6 weeks of age, which show mild ketosis with mild lactic acidosis.

She had a normal initial motor development, with head control recognized at 3–4 months. Later infantile motor development was mildly delayed, and she could walk unassisted at 14 months. However, an unstable gait persisted thereafter. She developed meaningful mono- and di-syllabic, single word speech at 16 months of age but remains unable to form 2-word sentences and relies heavily on gesturing to convey herself. A normal electroencephalogram showed the absence of epileptic encephalopathy, hence therapy was started.

She soon presented at the emergency room with episodic fast breathing at 21 months. Her neurologic exam showed dysconjugate gaze, mild hypotonia, dysmetria, ataxia, and an extensor plantar response. Hypertrichosis was appreciated as well. Arterial blood gas showed compensated metabolic acidosis and plasma lactate was 6.8 mmol/L. She was treated and maintained on sodium bicarbonate. MRI with magnetic resonance spectroscopy (MRS) (Figure 1) showed symmetrical and well-defined low T1 and high T2/FLAIR signals on the parieto-temporo-occipital white matter as well as medial cerebellar peduncles, pons, and medulla. Lactate peak was also seen. She was started on a mitochondrial cocktail consisting of CoQ10, riboflavin, carnitine, alpha-lipoic acid, vitamin C, and vitamin E.

At 26 months of age, she began to exhibit intention tremors for which she was started on carbidopa-levodopa with poor response. Extremity muscle atrophy was also observed to be developing.

Subsequent tests showed normal-sized kidneys and normal echocardiographic findings. Electromyography and nerve conduction studies showed myopathic patterns and multiple abnormal

findings in the nerve conduction test signifying various degrees of denervation.

Genetic testing for mitochondrial disorders using sequence analysis and deletion testing of the mitochondrial genome was negative and identified no pathogenic variant. Further testing using whole exome sequence analysis was done and revealed an A1577S variant of uncertain significance in the *DYNC1H1* gene. Both parents underwent gene testing as well. Her father had the same mutation, but was asymptomatic.

The patient was the second child of non-consanguineous second marriages. The first child of the union was a boy, also diagnosed with Leigh syndrome and presented at one-and-a-half years old with ptosis, ophthalmoplegia, and later with motor regression and tremors. His MRI/MRS (Figure 2) showed progressive symmetric widespread signal abnormalities involving the supratentorial and infratentorial compartments with predominant involvement of the brainstem, medial cerebellar hemisphere, and dorsal putamen bilaterally with parenchymal volume loss. A prominent lactate doublet and decrease in absolute concentration of the NAA peak - findings consistent with a mitochondrial disorder, were seen. Unfortunately, before any genetic testing could be pursued, he went into respiratory failure and died at 3 years of age.

Aside from her brother, the family genogram (Figure 3) revealed no significant illness that would indicate a mitochondrial or hereditary neurodegenerative disease, and all other half-siblings from both parents' first marriages showed no signs of neurologic disorder.

DISCUSSION

Leigh syndrome and Leigh-like syndrome are rare, inherited neurodegenerative disorders with characteristic pathological features usually presenting in infancy or early childhood. Its discovery is credited to the British neuropathologist Denis Archibald Leigh in 1951, through his post-mortem findings of a 7-month-old infant. Several authors have since attributed the defect in Leigh syndrome as a disorder in glucose metabolism,[7-10] causing elevations in lactate and pyruvate in the CSF of affected patients. [11] Rahman, et al. introduced a Leigh-like syndrome and attributed this to a mitochondrial disorder due to a broad range of genetic mutations in both nuclear

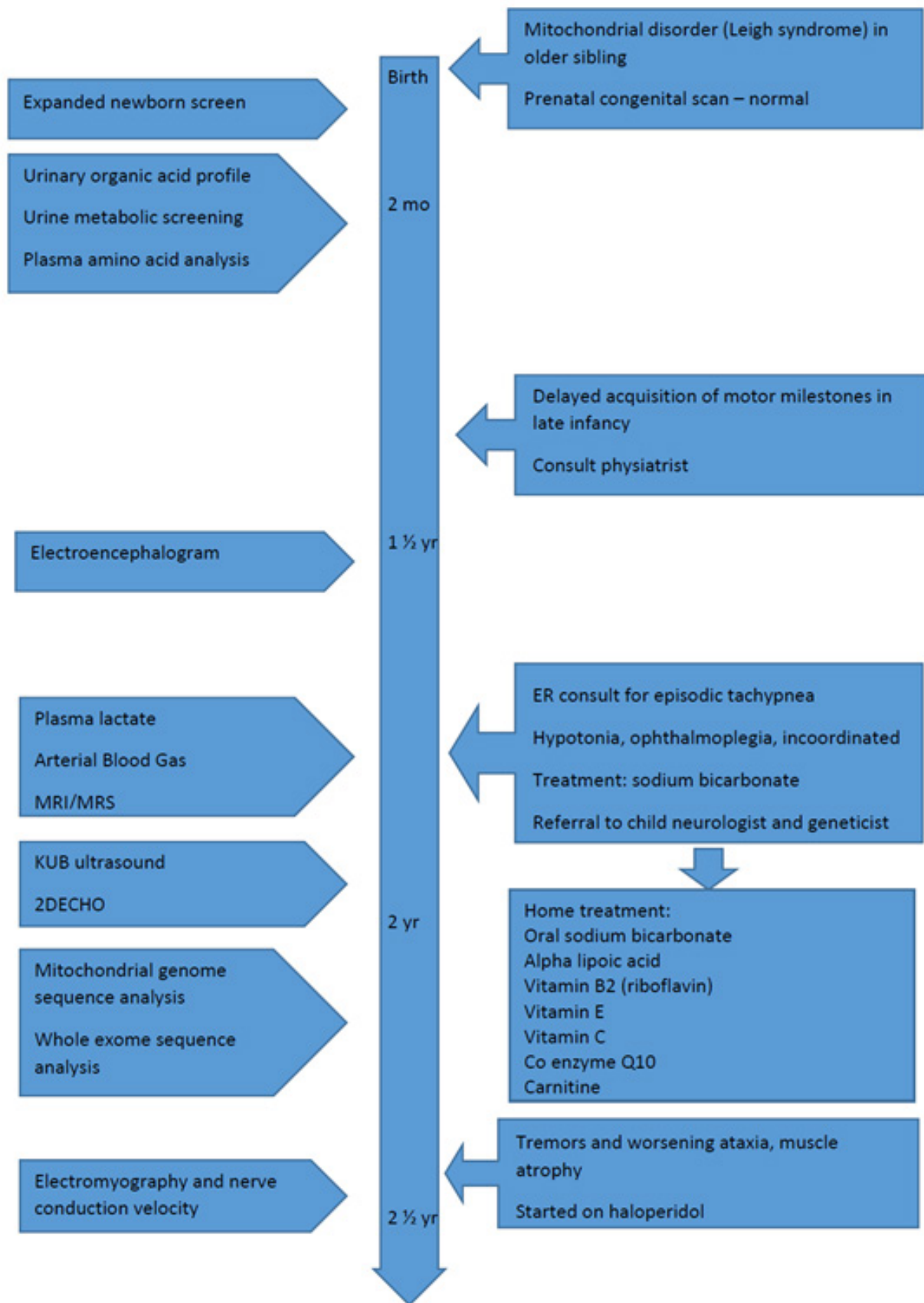
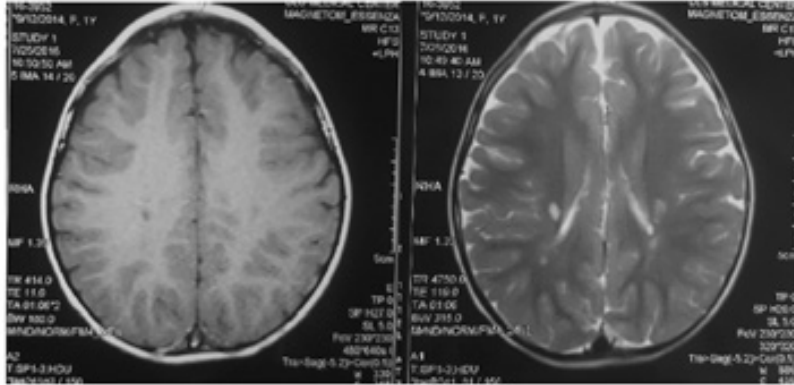
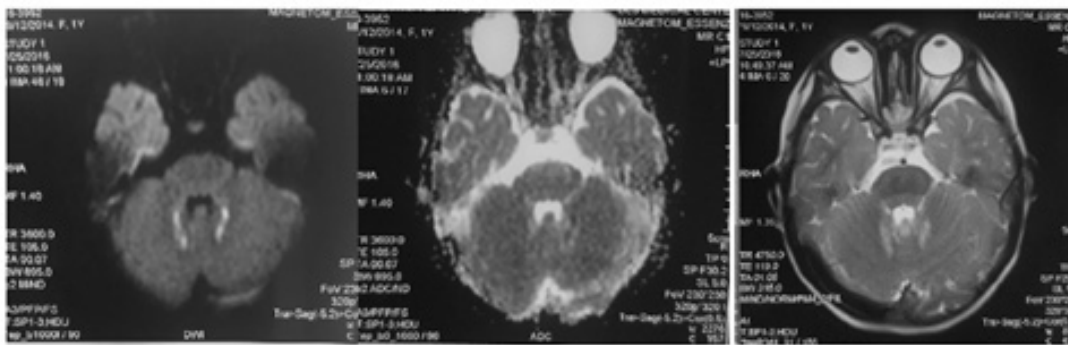


Figure 1. Case approach Leigh Syndrome: Timelines

A. Almost symmetrical and well-defined slightly low T1 and high T2/FLAIR signal in both parietal periventricular white matter.



B. High DWI and moderately low ADC signal changes in bilateral medial cerebellar peduncles, with corresponding high intensity signal in T2FLAIR.



C. On MRS, NAA is generally depressed, choline is minimally to moderately elevated with a decreased NAA/choline ratio, and moderate lactate elevation.

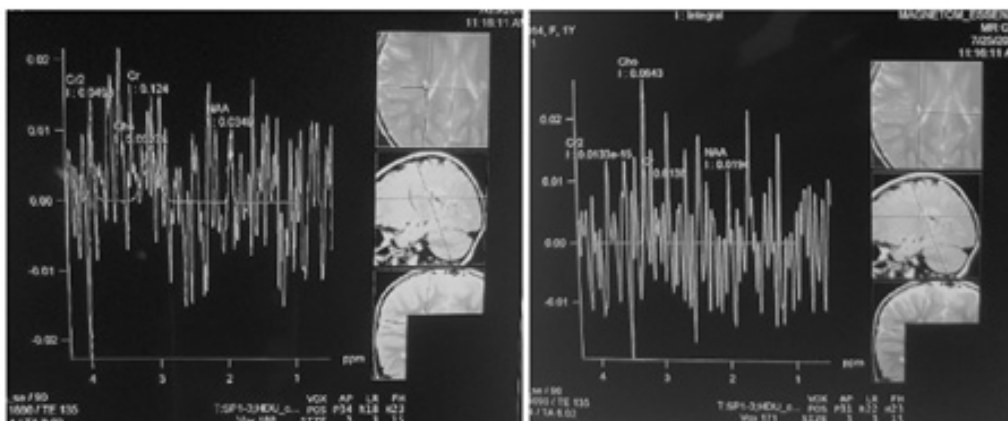


Figure 2. Case of Leigh Syndrome: MRI and MRS done at 1 year and 10 months

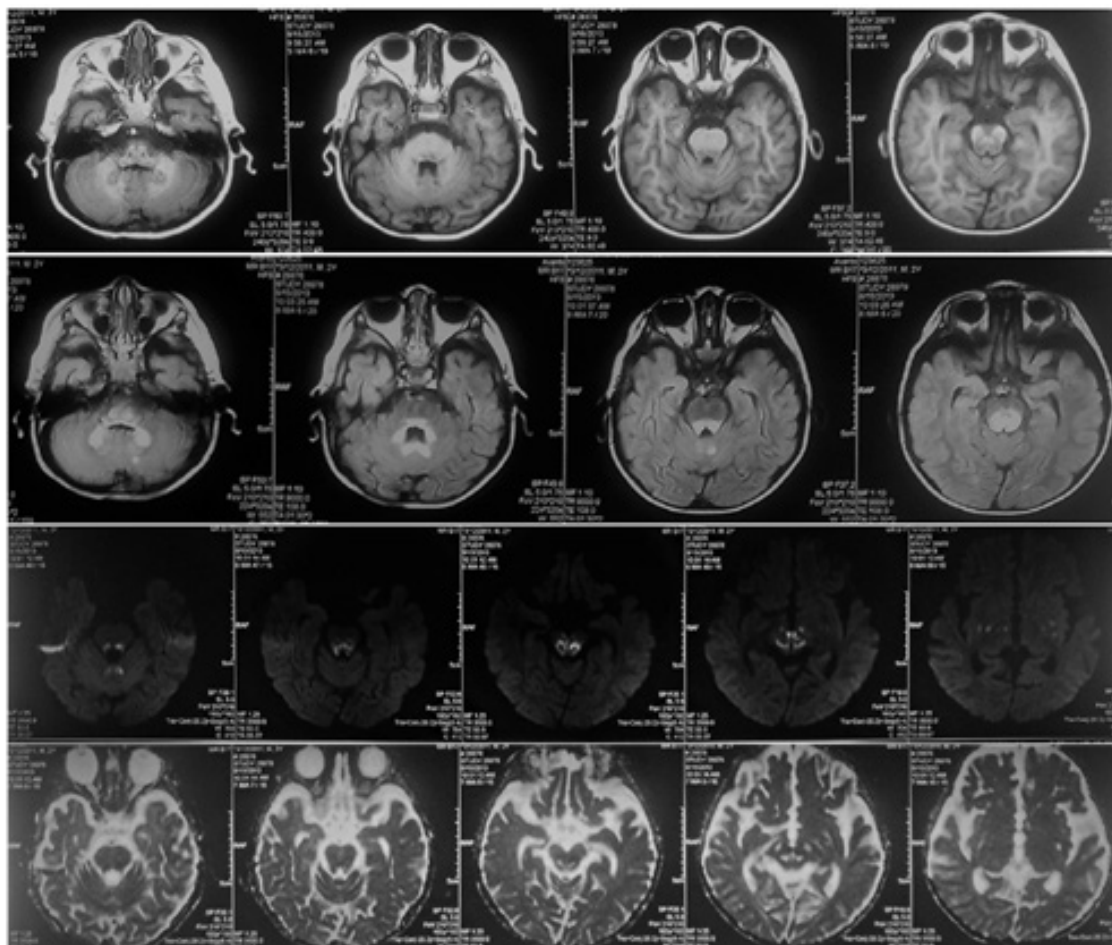


Figure 3. Case of Leigh Syndrome: Sibling MRI done at two-and-a-half years of age. Symmetric non-enhancing signal abnormalities involving the dorsal brainstem and medial cerebellar hemispheres with restricted diffusion in the corresponding areas. Prominent parenchymal volume loss is appreciated as well.

DNA (nDNA) and mitochondrial DNA (mtDNA) (Table 4).[5,12,13]

Whether it is a result of nDNA- or mtDNA-encoded mutation, most pathological gene mutations are ultimately involved in the process of energy production in the mitochondria. Ultimately, it is impaired oxidative phosphorylation (OXPHOS) that leads to a critical nadir of cellular energy and subsequent cell death. In the majority of cases, dysfunction of the respiratory chain (particularly complexes I, II, IV, or V), of coenzyme Q, or of the pyruvate dehydrogenase complex are responsible for the disease.[6,14]

It was apparent that there was no well-defined correlation between the basic defect to the clinical phenotype.[5,6] Hence, the distinction between Leigh syndrome and Leigh-like syndrome has been based on the fulfilment of stringent diagnostic criteria (Table 1, 2, and 3). Baertling, et al. described diagnostic criteria that allows for the diagnosis of Leigh syndrome in the absence of raised lactate

levels.[15] Whereas “Leigh-like syndrome” can be used for those who present with features strongly suggestive of Leigh syndrome but may have atypical neuropathology, normal or atypical neuroimaging, normal blood and CSF lactate levels, and/or incomplete evaluation.[5] Hence, in most cases, the diagnosis can be made without requiring neuropathologic confirmation.

The radiologic hallmarks of the disease are bilaterally symmetrical hyperintense signal abnormality evidenced over the basal ganglia, brainstem, or both—particularly vulnerable structures that are highly dependent on glucose consumption,[5,12,15,16] hence showing remarkable localization, congruent to the original histologic report by Leigh.[1]

MRS is an important tool for the monitoring of mitochondrial diseases, even if it is not specific and can show consequences of impaired oxidative phosphorylation such as elevated choline, elevated

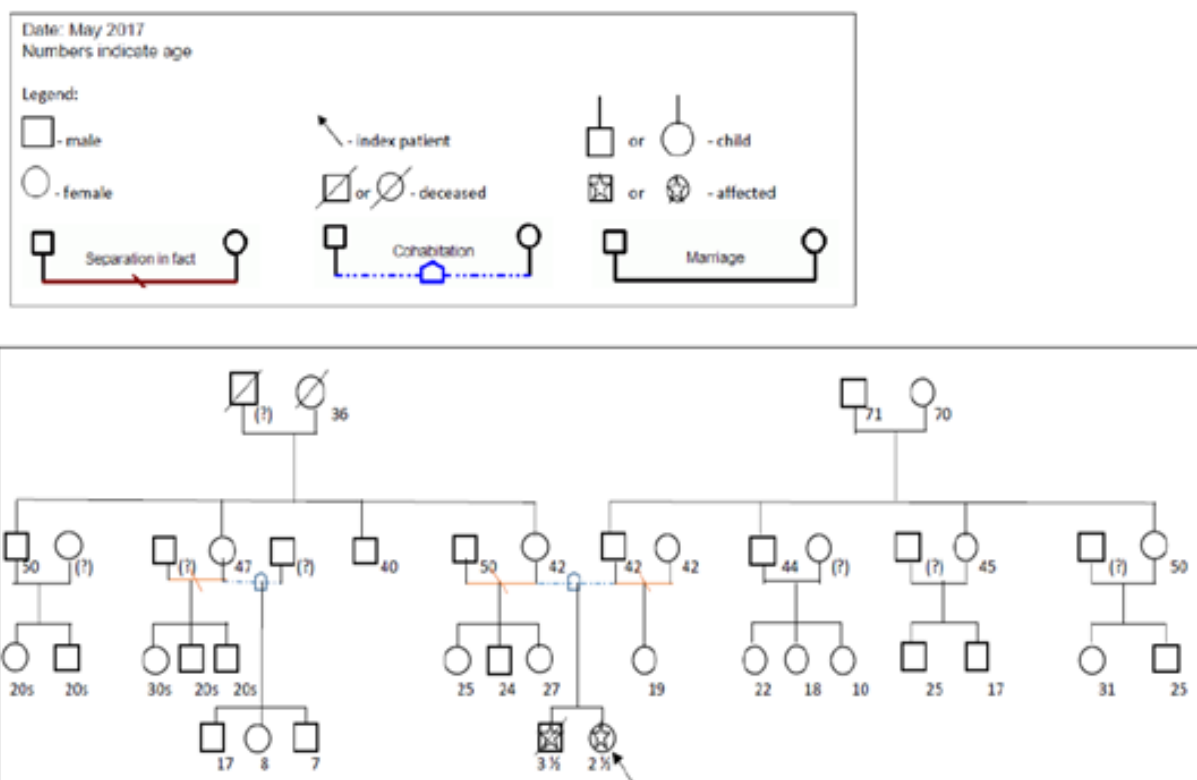


Figure 4. Case of Leigh Syndrome: Pedigree

lactate, and reduced N-acetylaspartate (NAA) due to the consequences of impaired oxidative phosphorylation. However, because of the phenotypic heterogeneity of mitochondrial disorders, the variability of disease states and regional sampling, some patients may not demonstrate marked lactate elevations. As such, diffusion characteristics and MRS characteristics vary depending on the acuity of the lesion.[16-18]

Presented is the second child of two children with a neurodegenerative disorder exhibiting an autosomal recessive pattern of inheritance. MRI and spectroscopy show findings consistent with mitochondrial disease, specifically Leigh syndrome. Enzymology, histology, and functional fibroblast ATP synthesis rate, and other molecular studies were not performed due to paucity of facilities and financial constraints.

As this was the second child affected with a similar disease process, genetic tests of the patient and both parents were facilitated, which yielded no significant mutation involved in mitochondrial disease on initial and second analysis.

An incidental finding of a novel dynein gene mutation with autosomal dominant transmission and uncertain significance was detected. This

initially led us to postulate that this may have some contribution in the case, as several studies have indirectly supported the involvement of cytoplasmic dynein (or dynein) in neurodegeneration[19-23] as well as various neurodevelopmental conditions. [20,22-25] However, later test results of paternal genes revealed the same mutation. Hence, this was deemed non-contributory to the patient's disease process. Indeed, as of the writings of this case, no dynein gene mutation has been directly linked to the development of Leigh or Leigh-like syndrome.

Despite the remarkable number of established disease genes and novel mutations being discovered, many cases of Leigh syndrome remain without a genetic diagnosis, indicating that there are still more disease genes to be identified.[26-29] The absence of an identifiable genetic mutation supports the hypotheses of Rahman, et al. that different phenotypes of Leigh and Leigh-like syndrome are more likely determined by the degree of impairment of energy production in certain brain regions rather than by specific gene involvement.[5]

Management for most cases of Leigh syndrome and Leigh-like syndrome was supportive care and surveillance of disease progression. Apart from targeted therapies, all Leigh syndrome patients can

Table 1. Case of Leigh Syndrome: Summary of Events

Date	Summary visit	Diagnostics	Intervention
September 2014	Birth	Expanded newborn screening	Anticipatory guidance
November 2014	Well baby visit Surveillance for mitochondrial disease	Urinary organic acid profile: Slightly increased lactate and hydroxyisobutyrate suggests mild lactic acidosis. Slightly increased 3-hydroxyisovalerate and trace 2-ethylhydracrylate suggests mild ketosis Urine metabolic screen: Amino acid profile: increased alanine Suggest plasma lactate, anion gap determination, urine organic acid analysis Plasma amino acid analysis: Cysteine is outside normal value, may not be significant. Essentially normal	Observation Anticipatory guidance
March 2016	Consult physiatrist for developmental delay	EEG – normal	Observation Therapy
July 2016	ER consult for tachypnea Hypertrichosis, ophthalmoplegia, hypotonia, ataxia, dysmetria Referral to child neurologist Referral to geneticist	Lactate: 6.8mol/L (n.v. 0.4-2) ABG: compensated metabolic acidosis MRI: almost symmetrical abnormal signal changes involving both parietal and temporo-occipital periventricular white matter; medial cerebellar peduncle and ponto medullary areas MRS: compatible with neuronal destruction with elevated lactate	Oral sodium bicarbonate Alpha lipoic acid Vitamin B2 (riboflavin) Vitamin E Vitamin C Carnitine Co enzyme Q10
August 2016	Cardiology consult	KUB UTZ – normal 2decho – normal	
September 2016		Mitochondrial genome sequence analysis: no pathogenic variant Whole exome sequence analysis: No variant associated with reported phenotype. Variant (pA1577S) of uncertain significance in DYNC1H1 with autosomal dominant transmission	
December 2016	Tremors and worsening ataxia, atrophy		Haloperidol
February 2017		EMG-NCV: myopathic pattern with denervation	
April 2017		Parental Whole exome sequence: similar variant (DYNC1H1 pA1577S) in paternal sample. None in maternal sample.	
May 2017		Reanalysis of subject's genetic material at a mitochondrial research institution	

be offered treatment for symptoms such as acidosis, seizures, dystonia, and cardiomyopathy. It was also important to ensure good nutrition, aggressive management of intercurrent illnesses, and caution with anesthesia (Table 4).

Genetic counselling is part of the management of neurodegenerative syndromes such as Leigh

syndrome. Being able to recognize the genetic or biochemical basis is important for guiding treatment options. In some cases, it can enable lifesaving interventions for the genetic forms that are most responsive to treatment. Further investigations in search of the cause for this phenomenon must be undertaken.

Table 2. Diagnostic criteria for Leigh syndrome (Rahman et al [1996])

-
- Progressive neurologic disease with motor and intellectual developmental delay
 - Signs and symptoms of brain stem and/or basal ganglia disease
 - Raised lactate concentration in blood and/or cerebrospinal fluid (CSF)
 - One or more of the following:
 - Characteristic features of Leigh syndrome on neuroradioimaging
 - Typical neuropathologic changes: multiple focal symmetric necrotic lesions in the basal ganglia, thalamus, brain stem, dentate nuclei, and optic nerves. Histologically, lesions have a spongiform appearance and are characterized by demyelination, gliosis, and vascular proliferation. Neuronal loss can occur, but typically the neurons are relatively spared.
 - Typical neuropathology in a similarly affected sibling
-

Table 3. Diagnostic criteria for Leigh syndrome (Baertling et al [2014])

-
- Neurodegenerative disease with variable symptoms resulting from mitochondrial dysfunction
 - Mitochondrial dysfunction caused by a hereditary genetic defect
 - Bilateral CNS lesions that can be associated with further abnormalities in diagnostic imaging
-

Table 4. Diagnostic criteria of nuclear gene-encoded Leigh syndrome (Rahman et al [1996], Lake et al [2015])

-
1. Characteristic clinical presentation
 2. Bilateral symmetric T2-weighted hyperintensities in the basal ganglia and/or brain stem on brain MRI
 3. Elevated lactate in blood and/or cerebrospinal fluid (CSF)
 4. Either identification of pathogenic variants in a specific nuclear gene or exclusion of mutation of mtDNA.
-

If post mortem examination is performed, characteristic neuropathologic changes include: multiple focal symmetric necrotic lesions in the basal ganglia, thalamus, brain stem, dentate nuclei, and optic nerves. Histologically, lesions have a spongiform appearance and are characterized by demyelination, gliosis, and vascular proliferation. Although neuronal loss can occur, typically the neurons are relatively spared.

CONCLUSION

Leigh syndrome is an extremely genetically heterogeneous mitochondrial disorder. Many cases of Leigh syndrome remain without a genetic diagnosis, hence the diagnosis of Leigh syndrome remains based on characteristic clinical and radiologic findings. However, a specific defect must be identified if reliable genetic counselling is to be provided.

We identified a neurodegenerative disease in a child presenting with signs of mitochondrial dysfunction, with an older sibling who had a similar disorder. Both had an unspecified genetic mutation. Hence, it is important for healthcare professionals to be familiarized with, and to better understand this disease by pursuing genetic confirmation in order to provide anticipatory care and management.

Patient anonymity, consent and confidentiality

Written informed consent was obtained from the legal representative of the patient (mother) for

the writing and publication of this case report and accompanying images (MR images of both children). All information regarding the patient was kept in strict confidence and patient identifiers (such as name, geographic location, date of birth, contact number, etc.) are removed from the manuscript and presented images. The patient's anonymity and confidentiality is protected by non-disclosure of any personal information that will identify the individual when the study is published or presented. A breach of confidentiality may occur if the information is used in any other way.

Ethical approval

This case report has been written in accordance with the CARE case reports guideline 2016, and is approved by the Institutional Review Board of the University of Santo Tomas Hospital, as required by the institution for presentation.

Competing interests

The authors declare that they have no competing interests that may interfere with the presentation, review or publication of this case.

Table 5. Difference between mitochondrial and nuclear-gene encoded Leigh syndrome

	Mitochondrial DNA associated	Nuclear DNA associated
Prevalence	1:100,000 to 1:140,000 births	approximately 1:40,000
Clinical manifestations	Onset of symptoms typically between age three and 12 months Decompensation (often with elevated lactate levels in blood and/or CSF) during an intercurrent illness Psychomotor retardation or regression. Neurogenic muscle weakness, Retinitis pigmentosa Hypotonia Spasticity Movement disorders (including chorea) Cerebellar ataxia Peripheral neuropathy Hypertrophic cardiomyopathy.	Onset of symptoms typically between ages three and 12 months. Later onset (including in adulthood) and long-term survival may occasionally occur Decompensation (often with elevated lactate levels in blood and/or CSF) during an intercurrent illness. Psychomotor retardation or regression, often followed by transient or prolonged stabilization or even improvement, but inevitably resulting in eventual progressive neurologic decline, typically occurring in stepwise decrements. Ptosis Hypotonia Spasticity Movement disorders (including chorea) Cerebellar ataxia Peripheral neuropathy Muscle weakness Hypertrophic cardiomyopathy Hypertrichosis Anemia Renal tubulopathy Liver involvement

(Continued...)

Acknowledgments

The authors would like to greatly thank Professor David Thorburn and his staff at the Murdoch Children's Research Institute for

assisting in reanalysis of the genetic file, and Dr. Mary Anne D. Chiong for her valuable advice in this case.

Table 5. Difference between mitochondrial and nuclear-gene encoded Leigh syndrome (Continued...)

	Mitochondrial DNA associated	Nuclear DNA associated
Inheritance	Maternal inheritance	Autosomal recessive or X-linked manner
Management	No specific treatment	<p>Specific treatment for the three nuclear gene-encoded Leigh-like syndromes:</p> <p>Biotin (5-10 mg/kg/day) and thiamine (in doses ranging from 300-900 mg) should be given for biotin-thiamine-responsive basal ganglia disease (BTBGD),</p> <p>5-10 mg of oral biotin per day for biotinidase deficiency</p> <p>Supplementation with oral coenzyme Q10 (10-30 mg/kg/day in children and 1200-3000 mg/day in adults) with coenzyme Q10 deficiency caused by mutation of PDSS2.</p> <p>Treatment of acidosis, seizures, dystonia, and cardiomyopathy</p>
Supportive treatment:	<p>Sodium bicarbonate or sodium citrate for acidosis</p> <p>Antiepileptic drugs for seizures.</p> <p>Dystonia is treated with benzhexol, baclofen, tetrabenzazine, and gabapentin alone or in combination, or by injections of botulinum toxin.</p> <p>Anticongestive therapy may be required for cardiomyopathy.</p>	<p>Follow up at regular intervals (typically every 6-12 months) to monitor progression and the appearance of new manifestations.</p>
Surveillance:	<p>Neurologic, ophthalmologic, and cardiologic evaluations at regular intervals to monitor progression and appearance of new symptoms.</p>	<p>Neurologic, ophthalmologic, audiologic and cardiologic evaluations are recommended.</p>
Agents/ circumstances to avoid:	<p>Sodium valproate and barbiturates, anesthesia, and dichloroacetate (DCA).</p>	<p>Sodium valproate, barbiturates, and dichloroacetate.</p>

REFERENCES

1. Leigh D. Subacute necrotizing encephalomyelopathy in an infant. *Journal of Neurology, Neurosurgery & Psychiatry* [Internet]. 1951 Aug 1;14(3):216–21. Available from: <http://dx.doi.org/10.1136/jnnp.14.3.216>
2. Van Maldergem L, Trijbels F, DiMauro S, Sindelar PJ, Musumeci O, Janssen A, et al. Coenzyme Q-responsive Leigh's encephalopathy in two sisters. *Ann Neurol* [Internet]. 2002 Nov 23;52(6):750–4. Available from: <http://dx.doi.org/10.1002/ana.10371>
3. Morris AAM, Leonard JV, Brown GK, Bidouki SK, Bindoff LA, Turnbull DM, et al. Deficiency of respiratory chain complex I is a common cause of Leigh disease. *Ann Neurol* [Internet]. 1996 Jul;40(1):25–30. Available from: <http://dx.doi.org/10.1002/ana.410400107>
4. DiMauro S, de Vivo DC. Genetic heterogeneity in Leigh syndrome. *Ann Neurol* [Internet]. 1996 Jul;40(1):5–7. Available from: <http://dx.doi.org/10.1002/ana.410400104>
5. Rahman S, Blok RB, Dahl H-HM, Danks DM, Kirby DM, Chow CW, et al. Leigh syndrome: Clinical features and biochemical and DNA abnormalities. *Ann Neurol* [Internet]. 1996 Mar;39(3):343–51. Available from: <http://dx.doi.org/10.1002/ana.410390311>
6. Gerards M. Leigh syndrome: the genetic heterogeneity story continues. *Brain* [Internet]. 2014 Oct 17;137(11):2872–3. Available from: <http://dx.doi.org/10.1093/brain/awu264>
7. Clark DB. Infantile subacute necrotizing encephalopathy. In: Saunders WB, editor. *Textbook of Pediatrics*. Philadelphia; 1964.
8. Hommes FA, Polman HA, Reerink JD. Leigh's encephalomyelopathy: an inborn error of gluconeogenesis. *Archives of Disease in Childhood* [Internet]. 1968 Aug 1;43(230):423–6. Available from: <http://dx.doi.org/10.1136/adc.43.230.423>
9. Gordon N, Marsden HB, Lewis DM. Subacute necrotizing encephalomyelopathy in three siblings. *Developmental Medicine & Child Neurology* [Internet]. 2008 Nov 12;16(1):64–72. Available from: <http://dx.doi.org/10.1111/j.1469-8749.1974.tb02713.x>
10. Gilbert EF, Arya S, Chun R. Leigh's necrotizing encephalopathy with pyruvate carboxylase deficiency. *Arch Pathol Lab Med*. 1983 Apr;107(4):162–6. PMID: 6402999.
11. Erven PMM, Gabreëls FJM, Ruitenbeek W, Renier WO, Lamers KJB, Sloof JL. Familial Leigh's syndrome: association with a defect in oxidative metabolism probably restricted to brain. *J Neurol* [Internet]. 1987;234(4):215–9. Available from: <http://dx.doi.org/10.1007/BF00618253>
12. Rahman S, Thorburn D. Nuclear Gene-Encoded Leigh Syndrome Overview. 2015 Oct 1. In: Pagon RA, Adam MP, Ardinger HH, et al., editors. *GeneReviews*® [Internet]. Seattle (WA): University of Washington, Seattle; 1993–2017.
13. Thorburn DR, Rahman J, Rahman S. Mitochondrial DNA-associated Leigh syndrome and NARP. In: *GeneReviews*® [Internet]. University of Washington, Seattle; 2017.
14. Finsterer J. Leigh and Leigh-like syndrome in children and adults. *Pediatric Neurology* [Internet]. 2008 Oct;39(4):223–35. Available from: <http://dx.doi.org/10.1016/j.pediatrneurol.2008.07.013>
15. Baertling F, Rodenburg RJ, Schaper J, Smeitink JA, Koopman WJH, Mayatepek E, et al. A guide to diagnosis and treatment of Leigh syndrome. *Journal of Neurology, Neurosurgery & Psychiatry* [Internet]. 2013 Jun 14;85(3):257–65. Available from: <http://dx.doi.org/10.1136/jnnp-2012-304426>
16. Lee H-F, Tsai C-R, Chi C-S, Lee H-J, Chen CC-C. Leigh Syndrome: Clinical and neuroimaging follow-up. *Pediatric Neurology* [Internet]. 2009 Feb;40(2):88–93. Available from: <http://dx.doi.org/10.1016/j.pediatrneurol.2008.09.020>
17. Saneto RP, Friedman SD, Shaw DWW. Neuroimaging of mitochondrial disease. *Mitochondrion* [Internet]. 2008 Dec;8(5–6):396–413. Available from: <http://dx.doi.org/10.1016/j.mito.2008.05.003>
18. Saneto R, Ruhoy I. The genetics of Leigh syndrome and its implications for clinical practice and risk management. *TACG* [Internet]. 2014 Nov;221. Available from: <http://dx.doi.org/10.2147/TACG.S46176>
19. Banks GT, Fisher EM. Cytoplasmic dynein could be key to understanding neurodegeneration. *Genome Biol* [Internet]. 2008;9(3):214. Available from: <http://dx.doi.org/10.1186/gb-2008-9-3-214>
20. Chen X-J, Xu H, Cooper HM, Liu Y. Cytoplasmic dynein: a key player in neurodegenerative and neurodevelopmental diseases. *Sci China Life Sci* [Internet]. 2014 Mar 24;57(4):372–7. Available from: <http://dx.doi.org/10.1007/s11427-014-4639-9>
21. Eschbach J, Dupuis L. Cytoplasmic dynein in neurodegeneration. *Pharmacology & Therapeutics* [Internet]. 2011 Jun;130(3):348–63. Available from: <http://dx.doi.org/10.1016/j.pharmthera.2011.03.004>
22. The role of axonal transport and mitochondrial dysfunction in neurodegeneration – focusing on Huntington's disease. Summary of PhD Thesis. (n.d.).
23. Sheng Z-H. Mitochondrial trafficking and anchoring in neurons: New insight and implications. *Journal of Cell Biology* [Internet]. 2014 Mar 31;204(7):1087–98. Available from: <http://dx.doi.org/10.1083/jcb.201312123>
24. Fiorillo C, Moro F, Yi J, Weil S, Brisca G, Astrea G, et al. Novel dynein *DYNC1H1* neck and motor domain mutations link distal spinal muscular atrophy and abnormal cortical development. *Human Mutation* [Internet]. 2014 Jan 3;35(3):298–302. Available from: <http://dx.doi.org/10.1002/humu.22491>
25. Hertecant J, Komara M, Nagi A, Suleiman J, Al-Gazali L, Ali BR. A novel de novo mutation in *DYNC1H1* gene underlying malformation of cortical development and cataract. *Meta Gene* [Internet]. 2016 Sep;9:124–7. Available from: <http://dx.doi.org/10.1016/j.mgene.2016.05.004>
26. Lake NJ, Compton AG, Rahman S, Thorburn DR. Leigh syndrome: One disorder, more than 75 monogenic causes. *Ann Neurol* [Internet]. 2015 Dec 15;79(2):190–203. Available from: <http://dx.doi.org/10.1002/ana.24551>
27. Miryounesi M, Fardaei M, Tabei SM, Ghafouri-Fard S. Leigh syndrome associated with a novel mutation in the *COX15* gene. *Journal of Pediatric Endocrinology and Metabolism* [Internet]. 2016 Jan 1;29(6). Available from: <http://dx.doi.org/10.1515/jpem-2015-0396>
28. Xu B, Li X, Du M, Zhou C, Fang H, Lyu J, et al. Novel mutation of *ND4* gene identified by targeted next-generation

sequencing in patient with Leigh syndrome. *J Hum Genet* [Internet]. 2016 Oct 20;62(2):291–7. Available from: <http://dx.doi.org/10.1038/jhg.2016.127>

29. Veerapandiyan A, Chaudhari A, Traba CM, Ming X. Novel mutation in mitochondrial DNA in 2 siblings with Leigh syndrome. *Neurol Genet* [Internet]. 2016 Aug 16;2(5):e99. Available from: <http://dx.doi.org/10.1212/nxg.0000000000000099>



Open Access This article is licensed under a Creative Commons Attribution-NonCommercial-ShareAlike 4.0 International License, which permits use, share — copy and redistribute the material in any medium or format, adapt — remix, transform, and build upon the material, as long as you give appropriate credit, provide a link to the license, and

indicate if changes were made. You may do so in any reasonable manner, but not in any way that suggests the licensor endorses you or your use. You may not use the material for commercial purposes. If you remix, transform, or build upon the material, you must distribute your contributions under the same license as the original. You may not apply legal terms or technological measures that legally restrict others from doing anything the license permits. The images or other third party material in this article are included in the article's Creative Commons license, unless indicated otherwise in a credit line to the material. If material is not included in the article's Creative Commons license and your intended use is not permitted by statutory regulation or exceeds the permitted use, you will need to obtain permission directly from the copyright holder. To view a copy of this license, visit <https://creativecommons.org/licenses/by-nc-sa/4.0/>.